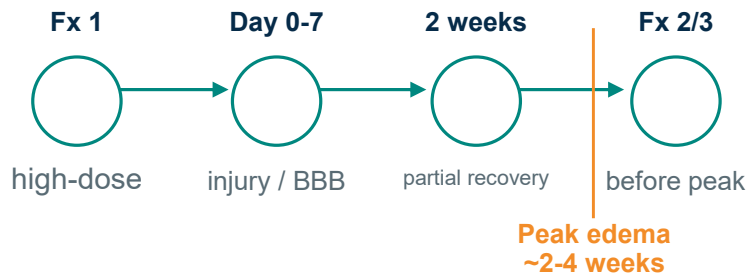


WHY TWO WEEKS?

Interval as a biological variable

For benign vestibular schwannoma, rapid repopulation is less relevant than preservation of cranial nerve function. Fraction timing may therefore be governed by vascular injury, BBB recovery, and edema evolution rather than malignant-tumor paradigms.

Pre-edema completion strategy



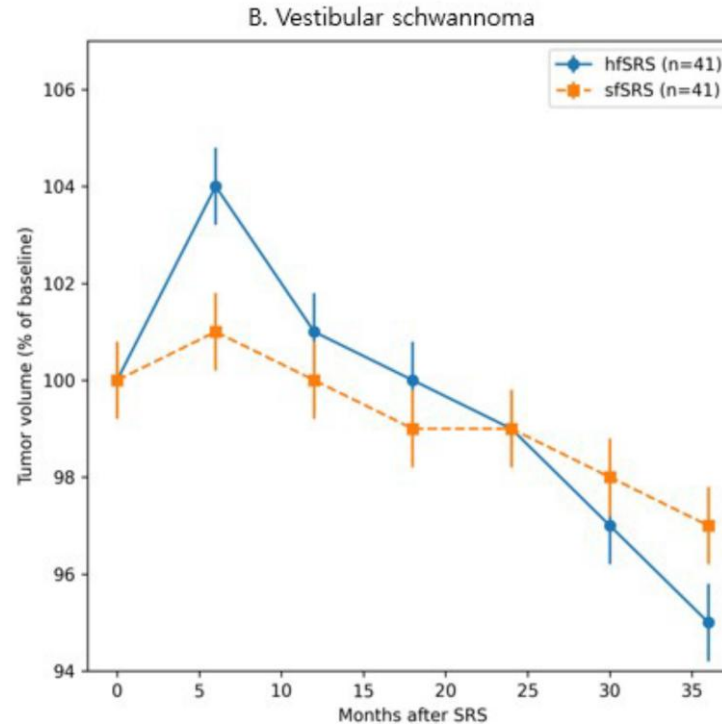
METHODS

Retrospective Gamma Knife cohort, 2016-2022
 VS treated with fixed 2-week interval hfSRS
 Mostly 3 fractions; volumetric MRI follow-up
 PSM comparison with sfSRS: 41 matched pairs

Median follow-up: 42 months

VOLUMETRIC KINETICS

hfSRS showed early transient expansion followed by later regression; long-term tumor control remained comparable.



Early enlargement should be interpreted as pseudoprogression, not treatment failure, when followed by stabilization/regression.

KEY OUTCOMES

Tumor control
97.6%
 hfSRS vs 100% sfSRS

Pseudoprogression
41.5%
 vs 19.5%, p=0.03

Functional hearing loss
40.0%
 vs 60.9%, p=0.17

Salvage for expansion
0
 transient enlargement only

CONCLUSION: Fixed two-week interval hfSRS achieved excellent VS control and revealed distinct, transient volumetric kinetics. Inter-fraction timing may be a biologically relevant treatment parameter.

Scan full article

