

Repeat stereotactic radiosurgery for deep-seated cerebral arteriovenous malformations in the basal ganglia, thalamus, corpus callosum, and brainstem

So Young Ji, MD^{1,2}, Ho Kang, MD^{1,2}, Kihwan Hwang, MD^{1,2}, Raheong Juh, PhD¹, Chae-Yong Kim, MD, PhD^{1,2}, Jung Ho Han, MD, PhD^{1,2}

¹ Department of Neurosurgery, Seoul National University Bundang Hospital, Gyeonggi-do, Republic of Korea

² Department of Neurosurgery, Seoul National University College of Medicine, Seoul, Republic of Korea

Background

The management of deep-seated cerebral arteriovenous malformations (AVMs), such as those in the thalamus, basal ganglia, and brainstem, poses significant challenges due to their high hemorrhagic risks and complex anatomical locations. Stereotactic radiosurgery (SRS) has been considered an alternative treatment for deep-seated AVMs, however, several studies have reported comparatively lower obliteration rates than for lesions in other locations. Repeat SRS has been proposed as a salvage strategy to improve obliteration and reduce hemorrhage risk, although radiation-induced complications in deep-seated eloquent regions may result in devastating deficits and limit subsequent interventions. Therefore, this study aimed to determine the radiological and clinical outcomes of patients managed with repeat SRS for deep-seated AVM after incomplete response to prior SRS.

Methods

We performed a retrospective analysis of patients with deep-seated cerebral AVMs treated with single-session SRS at our institution between 2009 and 2024. A total of 69 patients underwent SRS for deep-seated AVMs, of whom 34 patients who received repeat SRS were included in this study. Outcome measures consisted of AVM obliteration, post-SRS hemorrhage, and radiation-induced changes. AVM obliteration was assessed using cerebral digital subtraction angiography (DSA).

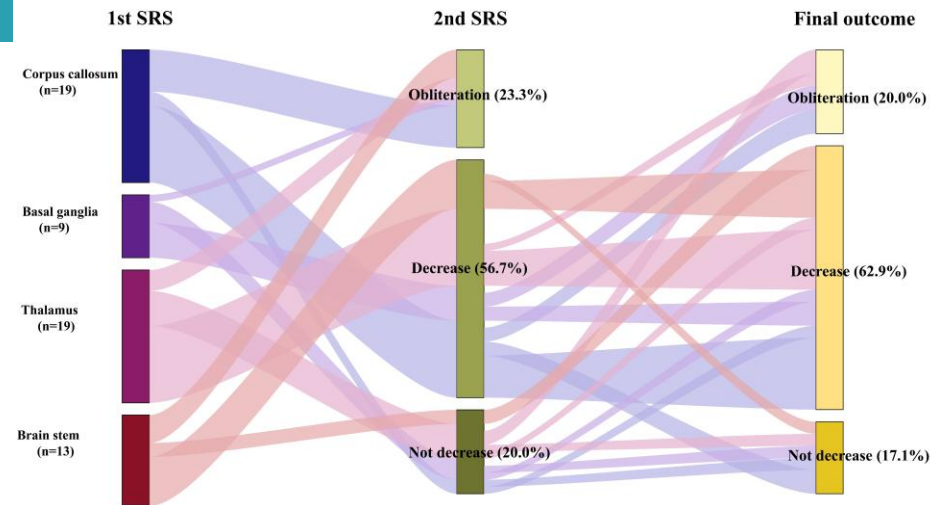


Figure 1. Sankey diagram demonstrating the distribution of treated AVMs according to location prior to the first and second radiosurgery procedures and at last follow-up.

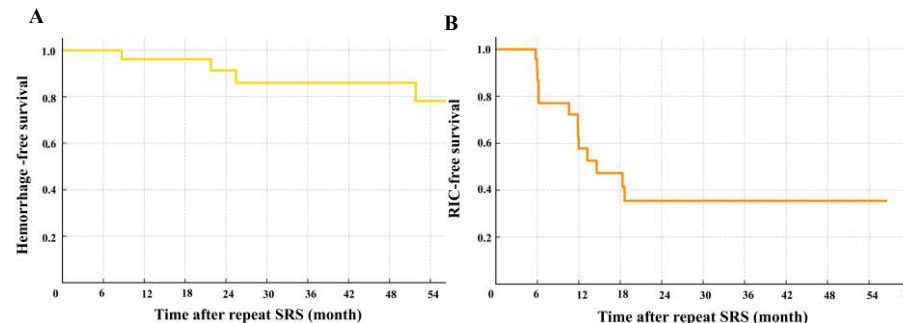


Figure 2. Kaplan–Meier curves showing clinical outcomes after repeat SRS for residual deep-seated AVMs: (A) hemorrhage-free survival, with a 3-year survival rate of 85.9%; and (B) radiation-induced change-free survival RFS, with a 3-year survival rate of 35.5%

Results

The study included 34 patients (20 males, 58.8%) who underwent repeat SRS for residual deep-seated AVMs. The median age at repeat SRS was 22.0 years (range : 6-55years). AVMs were primarily located in the corpus callosum (35.3%), thalamus (26.5%), brainstem (20.6%), and basal ganglia (17.6%). AVM obliteration was achieved in 23.3% of patients after first SRS, while 56.7% showed a reduction in nidus volume. At the time of repeat SRS, the median nidus volume was 1.3 cm³ (IQR: 4.8), and the median prescription dose was 16.0 Gy (IQR: 5.0) at the 50% isodose line. The median interval between the first and second SRS was 48.3 months (IQR: 21.0). During a median follow-up of 83.0 months (IQR: 61.5), the obliteration rate after second SRS was 20.0%, with an additional 62.9% showing a reduction in nidus volume. Hemorrhagic events occurred in 5 patients (14.7%) following the second treatment, including one fatality (2.9%). Lower initial radiation dose was significantly associated with an increased risk of hemorrhage ($p < 0.05$). Radiation-induced changes were identified in 17 patients (50.0%), among whom 4 (11.8%) manifested clinical symptoms.

Conclusion

Repeat SRS may be considered as a treatment option for residual deep-seated AVMs, offering additional potential for obliteration or nidus reduction. Given the substantial risk of radiation-induced changes, careful monitoring during long-term follow-up is essential