



The usefulness of stereotactic fractionated radiotherapy using Gamma Knife Icon mask system for relatively large brainstem metastases.

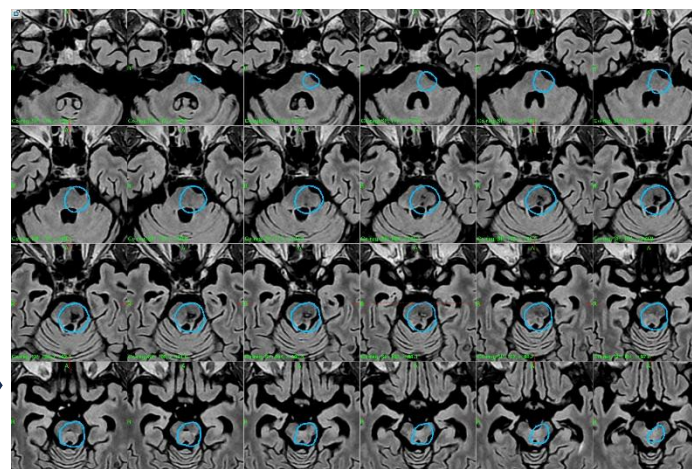
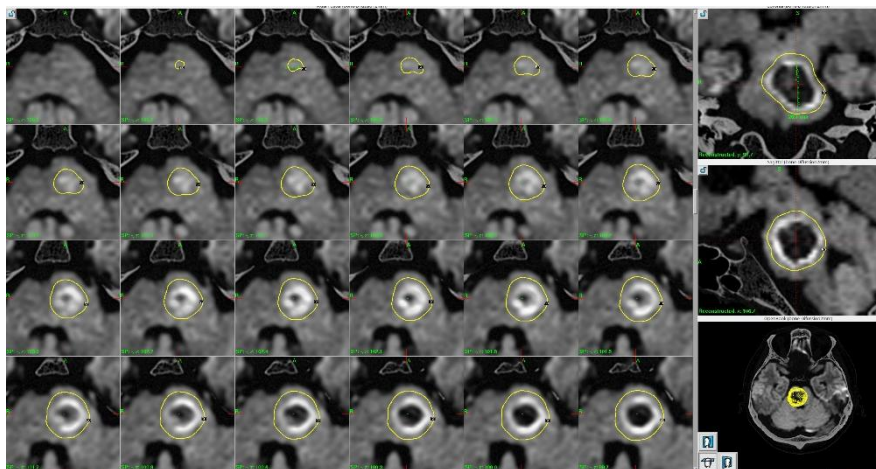
Takuya Kawabe, Manabu Sato Rakusai Shimizu HP, Kyoto, JAPAN

Objective: The effectiveness of stereotactic radiosurgery for brainstem metastases has already been demonstrated, but issues remain regarding local control in the long term and the volume limit of the target. Since the introduction of the Gamma Knife Icon, it has also become possible to perform fractionation with mask fixation. Therefore, we investigated the treatment outcomes of brainstem metastases exceeding 1 mL, among the cases in which stereotactic fractionated radiotherapy (SRT) was performed at our hospital.

Methods: We investigated 35 cases and 38 sessions using Icon SRT, including brainstem metastases exceeding 1 mL. The sites were 15 of midbrain, 19 of pons, and 1 case of medulla oblongata. The most common primary tumor was lung in 17, followed by breast in 10, gastro-intestinal tracts in 6, and other in 2 cases. The median volume of brainstem lesions was 3.1 mL. Brainstem lesions were the largest lesions in 22 cases. There were 33 cases of 10 fractions, 2 cases of 5 fractions, and 2 cases of 6 fractions. The median dose per fraction for 10 fractions was 3.7/6.4 Gy.

Results: The median survival time after SRT was 11.9 months, and the incidence of neurological death was 6/12/24/36 months was 11/15/19/26%. Local control failure was 8/17/17/17% at 6/12/24/36 months, and quality of life was maintained in 87/78/72/69% at 6/12/24/36 months, with no serious complications.

Conclusions: SRT is suggested to be an effective treatment for medium-sized to relatively large brainstem metastases, including functional prognosis.



70s man
Lung adenocarcinoma (ALK+) CR: MTA
(Drug free for 2years)
Gait disturbance
Tumor volume 8.4mL
max. diameter 27.2mm
3.2Gy x 10Fr

37 months after GKRT
No recurrence of BSM