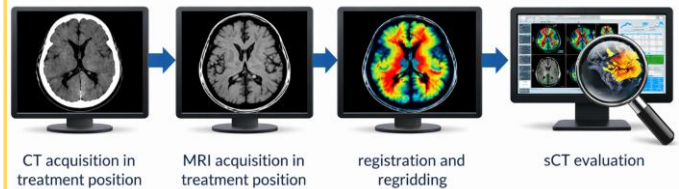


A. Halley, V. Fave, J. Bouveret, A. Champion, D. Benzaquen, M. Levivier
 Hôpital de La Tour, Radio-Oncology department, Meyrin/Geneva, Switzerland.

- ✓ Evaluation of a synthetic CT (sCT) : MRCAT Brain solution (v.5.7.1, Philips Oy, Vantaa, Finland).
- ✓ Deep-learning method for sCT generation from a T1w 3D mDixon MR sequence.

Patients and Methods

- ✓ **Cohort** : 47 patients and 71 tumors (metastases, meningiomas, vestibular schwannomas).
- ✓ **Evaluation workflow** :



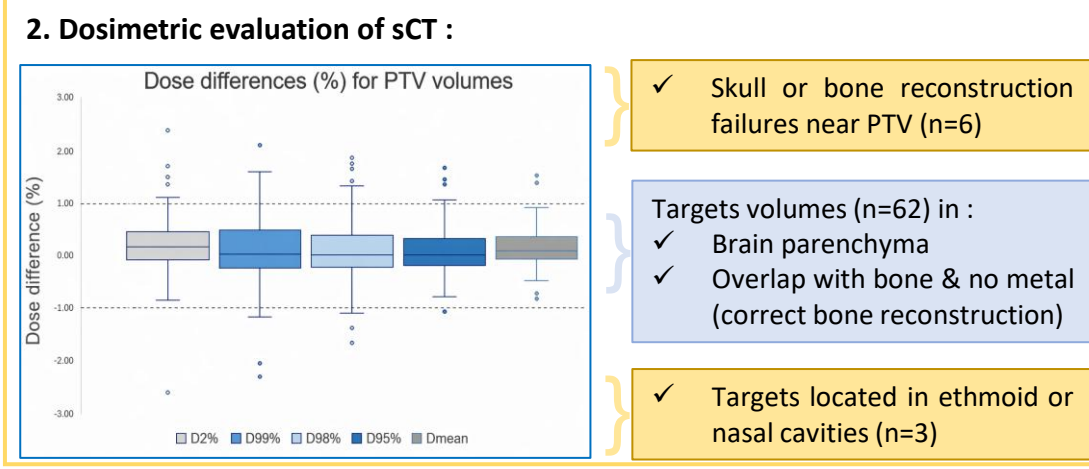
- Assessment criteria :**
1. Image quality (Hounsfield Unit comparison)
 2. Dosimetric evaluation
 3. Organ at risk auto-segmentation accuracy
 4. Patient-specific distortion evaluation
 5. Qualitative evaluation of contouring

Main results

- ✓ **Metastases** : Most cases showed excellent dosimetric agreement and acceptable sCT quality.
- ✓ **Meningiomas** : Overall dosimetric agreement was good, attention is required at bone or air interfaces (with dose differences outside target volume > 5%).
- ✓ **Vestibular schwannomas** : Good dosimetric correlation but imperfect temporal bone reconstruction led to inaccurate cochlea contour and influenced target delineation.

- 1. Image quality of sCT :**
- ☐ **Median Mean Absolute Error (MAE) < 25 HU** (PTV, Brain, Eyes).
 - ☐ **Main limitations** : Bone median MAE = 227.1 HU. Bone reconstruction around postoperative sites or at sinus interfaces. Overestimation of air cavities on sCT. Temporal bone along ear canal was (partly) missing on some slices.

- 2. Dosimetric evaluation of sCT :**
- ☐ **Gamma analysis** : 97.2% of cases passed a gamma rate ≥ 95% with 1%/1mm criterion.



- 3. OAR auto-segmentation on sCT :**
- ☐ **Median Dice Similarity Coefficient > 0.9** (Bone, Brain, Brainstem, Eyes).
 - ☐ Lower congruence of DSC for optic nerves, cochleas and chiasm.

4. Patient specific distortion evaluation :

MR sequences	Maximum distortion (mm)
T1w 3D mDixon (sCT generation)	± 0.49
Used for delineation	± 0.18 to 0.69

- ✓ This works supports the feasibility of a MR-only workflow for selected brain tumor cases.
- ✓ Anatomical context strongly influences sCT performance with largest limitations near bone-air interfaces.
- ✓ As CT is often used for MR distortion QA, further investigation is needed to evaluate if using only a sCT increases the risk of missing MR distortion.