



Immobilizing the Jaw During Stereotactic Radiosurgery for Lesions Extending Beyond Temporomandibular Joint: An Avant-Garde Approach for a Quick, Reversible, Non-Invasive, Radiolucent and Reliable Fixation

ISRS 2026
SYDNEY, AUSTRALIA
31ST MAY - 3RD JUNE

Adesh Shrivastava, Manjul Tripathi

AIIMS, Bhopal, India & Postgraduate Institute of Medical Education and Research, Chandigarh, India

Keywords: Intermaxillary fixation | Jaw immobilization | Radiosurgery | Schwannoma Temporomandibular joint

INTRODUCTION

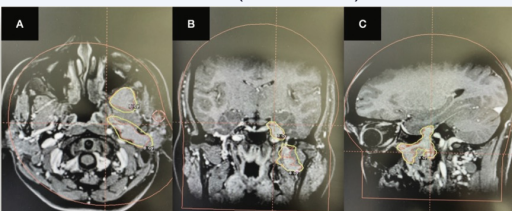
Gamma Knife Radiosurgery (GKRS) requires strict target immobilization. Lesions extending into extracranial locations — particularly near the temporomandibular joint (TMJ) — pose a unique challenge due to physiological jaw movement during image acquisition and radiation delivery.

- > Conventional methods use titanium screws for intermaxillary fixation — an invasive procedure causing MRI artefacts
- > Metal arch bars and braces are incompatible with MRI imaging
- > A non-invasive, MRI-compatible, radiolucent alternative was needed

CASE ILLUSTRATION

A 32-year-old female presented with intractable trigeminal neuralgia (BNI Grade V) and hypoesthesia in the left maxillary and mandibular distribution.

- > MRI revealed trigeminal nerve schwannoma extending from cavernous sinus to the subtemporal area via foramen ovale and rotundum
- > Lesion proximity to TMJ posed definite risk of target displacement with jaw movement
- > Treated with hypofractionated GKRS: 8 Gy at 50% isodose in 2 fractions (frame in situ)



Left trigeminal schwannoma involving the maxillary and the mandibular divisions extending in the subtemporal area near temporomandibular joint

THE TECHNIQUE — STEP BY STEP

1	2
Polymer orthodontic brackets applied to upper and lower dentition using light-cured composite fillers	Orthodontic elastics mounted on brackets to achieve intermaxillary fixation — no anesthesia required
3	4
Leksell stereotactic frame fixed under local anesthesia, kept subtly eccentric to center the tumor and avoid collision error	MRI acquired with 1mm non-overlapping cuts, co-registered with stereotactic CT to minimize error

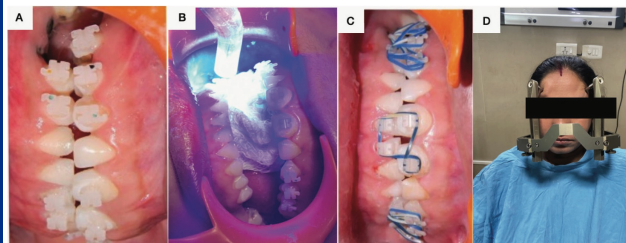


Fig. 2: (A) Polymer brackets on dentition; (B) Light-cured composite fillers; (C) Orthodontic elastics; (D) Eccentric frame fixation

Procedure duration: ~15 minutes | No discomfort | No anesthesia | Fully reversible between fractions for feeding

OUTCOME HIGHLIGHTS

15 Minutes for	0 Injections or	2 GKRS fractions
--------------------------	---------------------------	----------------------------

COMPARISON: FIXATION METHODS

Feature	Titanium Screws	Our Technique
Invasive procedure	Yes	No
MRI artefacts	Yes	No
Anesthesia required	Yes	No
Radiolucent	No	Yes
Reversible	Limited	Fully
Risk of tooth damage	Yes	No
Infection risk	Yes	No
Procedure time	30-45 min	~15 min

DISCUSSION

- > Frameless systems (ICON, CyberKnife) have improved extracranial lesion management but mandibular immobilization remains important for TMJ-region targets
- > The Marseille group demonstrated proof of concept with titanium screws in 3 patients — but invasiveness and MRI artefacts remained drawbacks
- > Our non-metallic polymer brackets and orthodontic elastics provide equivalent immobilization without any of these limitations
- > Prophylactic antiemetics are advisable with jaw immobilization to prevent vomiting risk

CONCLUSION

Orthodontic bracket-and-elastic jaw immobilization is a safe, accurate, quick, non-invasive, and MRI-compatible adjunct for GKRS targeting in extracranial and subtemporal regions. It extends the reach of Gamma Knife radiosurgery while maintaining targeting precision and patient comfort.

REFERENCES

- > Mukherjee KK, Tripathi M. Acta Neurochir (Wien) 2016;158:2237